

TRYPANOSOMA (HERPETOSOMA) RANGELI TEJERA, 1920: PRELIMINARY  
REPORT ON HISTOPATHOLOGY IN EXPERIMENTALLY INFECTED MICE

Cecilia de SCORZA (1), Servio URDANETA-MORALES (2) & Felix TEJERO (2)

S U M M A R Y

Male mice (NMRI strain) of 3 and 5 g were inoculated i. p. with  $8 \times 10^6$  and  $9 \times 10^4$  metatrypomastigotes/g harvested from a 12-day-old LIT culture of *Trypanosoma rangeli* of the "Dog-82" strain. At regular intervals after inoculation, the animals were sacrificed and portions of heart, liver, spleen, lung, thigh, kidney, stomach, intestine, brain, sternum, and vertebral column were embedded in paraffin, sectioned, and stained with haematoxylin-eosin and Giemsa colophonium. Pathology was encountered in the first five tissues cited above. The subcutaneous, periosteal, interstitial, and peribronchial connective tissues, and later the muscle cells of the heart, were heavily parasitized by amastigotes and trypomastigotes. The possible reasons for the decrease in tissue parasitosis at the same time that the parasitemia is reaching its peak, and for the low level of inflammation in the parasitized tissues, are discussed. The observations of other workers, as well as the results described here, indicate that certain strains of *T. rangeli* under certain conditions may well cause pathological alterations in mammals.

**KEY WORDS:** Experimental trypanosomiasis — *Trypanosoma* (Herpetosoma) rangeli Tejera, 1920 — mice

I N T R O D U C T I O N

Ever since DE LEON'S<sup>7</sup> report on the first human infections by *Trypanosoma rangeli* in Guatemala in 1934, many wild and domestic mammals have been identified as reservoir hosts for the parasite in Central and South America<sup>5,17</sup>. Most authors have considered *T. rangeli* to be non-pathogenic in humans URDANETA-MORALES and TEJERO<sup>29</sup> have now observed amastigote stages of *T. rangeli* which multiply by binary fission in various tissues of experimentally infected with mice. This paper presents the preliminary observations on the histopathology caused by this flagellate in suck-

ling mice intraperitoneally inoculated with metatrypomastigotes of *T. rangeli* harvested from LIT culture medium.

M A T E R I A L S A N D M E T H O D S

The culture and the experimental validation of the purity of the strain of *T. rangeli* used have been described by URDANETA-MORALES AND TEJERO<sup>28,29</sup>. Two groups of suckling male white mice (NMRI non-isogenic strain) were inoculated. In the first group, 12 mice of 3 g average weight received  $8 \times 10^6$  metatrypo-

Requests for reprints should be addressed to the second author.

- (1) Facultad de Ciencias, Departamento de Biología, Universidad de Los Andes, Mérida, 5101, Venezuela
- (2) Instituto de Zoología Tropical, Facultad de Ciencias Universidad Central de Venezuela, Apartado 47058, Caracas 1041-A, Venezuela

mastigotes/g i.p. from a 12-day-old LIT culture. One animal was sacrificed at 5, 18, and 24 hr post inoculation, and one other daily thereafter. Portions of heart, liver, spleen, lung, kidney, intestine, stomach, brain, sternum, the vertebral column with adjacent tissues and the whole thigh were then fixed in 10% formalin, processed in paraffin, sectioned at 5  $\mu$ , and stained with haematoxylin-eosin and Giemsa colophony<sup>3</sup>.

A second group of six 5 g mice received 9 x 10<sup>4</sup> metatrypomastigotes/g i.p. and two each were sacrificed at 3, 4, and 5 days postinoculation, being processed as above. Parasitemia was followed by daily examination of fresh preparations of tail blood<sup>4</sup> and also of thin smears fixed in methanol and stained with Giemsa. Microphotographs were taken as already described<sup>28</sup>.

### RESULTS

In both experimental groups, the parasitemias increased steadily up to the fourth day, at which they reach their peak values.

Blot films taken daily showed no signs whatever of trypomastigotes in division.

Table I shows the occurrence of *T. rangeli* in the various tissues at various intervals post-inoculation, omitting those tissues in which the parasites were never observed. It can be seen that the parasites were very abundant from 5 hr — 5 days post-inoculation in the subcutaneous connective tissue of the thigh, in the periosteal connective tissue of the femur, and in the interstitial connective tissue of the skeletal muscles associated with the thigh, vertebral column and the sternum (Fig. 1a). After 4 days, the parasites were fewer, and remained as such at least up to the tenth day. Enormous clusters of parasites were seen in the connective tissue, some within macrophages but the majority free. Form and size were highly variable; amastigotes and intermediate forms were seen, many with double nuclei and/or kinetoplasts (Fig. 1b). Some had apparently doubled themselves around a large vacuole, these being similar to certain stages intermediate between trypomastigote and amastigote seen by PAN<sup>18</sup> (Fig. 1a, arrows) in the intra-

myocellular nests of *T. cruzi* infections in mice. The cytoplasm of the parasites in the connective tissue was very weakly stained, but the nuclei and the kinetoplasts were strongly colored, often appearing free in the amorphous surrounding substance. At 5 and 18 hr. there were observed in some areas many macrophages with vacuolated cytoplasm, and at 24 hr, some accumulations of polymorphs, with a few monocytes, and also some degranulated mastocytes (Fig. 1c). There were no parasites visible in the fibers of the femoral, parafemoral, or pectoral muscles, although focal degeneration and destruction were observed in some of the fibers. Interstitial edema, fibroblastic proliferation, macrophages containing parasites (Fig. 1d), and discrete infiltration by polymorphs and monocytes were present in some areas; at some sites many free parasites with weakly stained cytoplasm, a large vacuole, and strongly stained kinetoplast were seen.

T A B L E I  
Correlation between tissue parasitosis and the after experimental inoculation of mice with *Trypanosoma* (*Herpetosoma*) *rangeli*

Hours	Tissue					
	Connective (subcutaneous, periosteal, interstitial)	Liver	Spleen	Lung	Heart	Bone Marrow
5	++++	—	+	—	—	++
18	++++	+	+	+	—	+
24	++++	+	+	+	—	+
48	++++	++	++	+++	+	+
72	++++	++	+	++	++++	—
96	+++	+	—	+	+	—
120	++	—	—	—	—	—

Grade of tissue parasitosis: ++++ = very intense  
+++ = intense  
++ = abundant  
+ = scanty  
— = absent

In the bone marrow, amastigotes were seen, the majority rather weakly stained, free or within macrophages. They were most abundant between 5 and 48 hr post-inoculation.

Parasites were observed in the liver from 18-96 hr post-inoculation, always in moderate numbers that showed an increase at 48 and 72 hr. Amastigotes of varying size were seen in the sinusoids and Kupffer cells (Fig. 2), without inflammatory reaction. The parasitosis

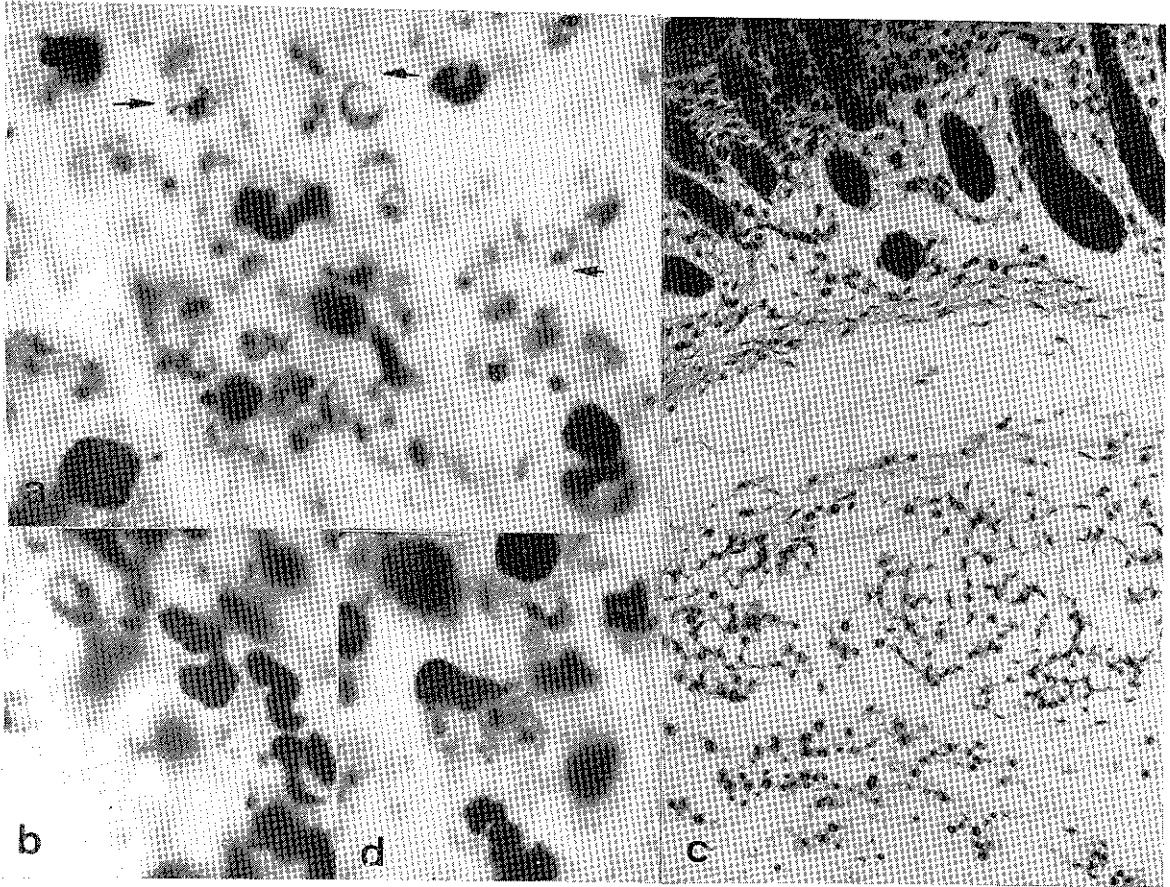


Fig. 1 — Histological sections from albino mice inoculated i.p. with metatrypomastigotes of *Trypanosoma rangeli* from LIT culture.

Section of skin from thigh, showing:

- a. High number of parasites in subcutaneous connective tissue. 5 hr post-inoculation (1400 X)
- b. Amastigote in division. 18 hr post-inoculation (1400 X)
- c. Phagocytic cells in subcutaneous connective tissue. 24 hr post-inoculation (300 X)
- d. Intracellular amastigotes in subcutaneous connective tissue. 24 hr post-inoculation (1400 X)

of the spleen was also discrete, being observed from 5-72 hr post-inoculation, amastigotes being seen in the sinusoids and macrophages of the red pulp. As in the liver, parasites were more strongly stained than in the connective tissue.

In the lung, parasites were seen at 18 hr post inoculation, reaching a maximum at 48 hr. Amastigotes were seen in the alveolar macrophages and some trypomastigotes were in the lumen of the alveoli. The greatest parasitic density was in the peribronchial connective tissue of the bronchi of medium caliber and in the adventitia of the blood vessels; the parasites were free and similar to those in the subcutaneous connective tissue. Amastigotes were

also seen in highly vacuolated macrophages, and some of them appearing to be within the peribronchial smooth muscle fibers. Groups of trypomastigotes were also seen in the lumen of some of the veins.

The first parasites in the heart were detected 48 hr. post inoculation; they were well-stained amastigotes, some with double nuclei. They formed small nests within the mesothelial cells of the epicardium and in the subepicardial macrophages, generally toward the apex of the heart. A few polymorphs, mononucleated cells and some degranulated mastocytes were seen. At this time, no parasites were observed to be within the myocells, but at 72 hr, they were

abundant in many nests of varying size within the myocells in all parts of the heart (Fig. 3). The parasites within the individual nests were extremely uniform in aspect, amastigotes predominant in some, while others contained mainly trypomastigotes or intermediate forms. Amastigotes were well stained, with basophilic cytoplasm and sometimes a double kinetoplast. Ruptured nests and various stages of free parasites, and amastigotes within macrophages were also seen. The frequent observation of amastigotes within the mesothelial cells of the epicardium and the endothelial cells of the endocardium, and of the veins of medium caliber was very striking; they were also seen in the lumen of some capillaries and veins. No inflammatory reaction was observed, only discrete foci of infiltration in the subendocardial region, with predominance of histiocytes and apparently free parasite nuclei and kinetoplasts.

## DISCUSSION

Results indicate that, under the experimental conditions described, the "Dog-82" strain of *T. rangeli* undergoes an early tisular reproductive cycle in the connective tissues (subcutaneous, periosteal, and the interstitial connective tissue of the skeletal muscles). Later, the liver, spleen, lungs, bone marrow, and finally the heart are invaded.

The heart is intensely, but very briefly parasitized, the parasites being seen only between the second and fourth days post-inoculation. The presence of amastigotes in the mesothelial cells of the epicardium, and later, in the endothelium of the endocardium and of some intramyocardial veins of medium caliber is an interesting phenomenon, not habitually seen in *T. cruzi* infections.

Upon comparing the levels of tissue parasitosis with the parasitemias reported above and also by URDANETA-MORALES and TEJERO<sup>29</sup> for this experimental model, we may suggest the progressive passage of tissue forms of the parasite toward the blood stream. Parasitemia attains its maximum between the fourth and eighth day post inoculation, while tissue parasitosis diminishes between the fourth and sixth days post-inoculation. There is no indi-

cation of reinvasion of the tissues, and the parasitemia progressively diminishes until the 17th day post-inoculation.

The scanty inflammation in the parasitized tissues may be due to the immature immunological system of the very young hosts and/or to the short time since infection in the animals. A weak, non specific immune response at the tissue level, with little destruction of parasites, is suggested by the presence of macrophages, occasionally abundant and containing parasites, by the sporadic foci of polymorphs in the connective tissues (subcutaneous, interstitial of the skeletal muscles, and the subendocardial region), and by groups of free parasite nuclei and kinetoplasts. The reasons for the disappearance of the parasite from the blood are unknown, though ANEZ et al.<sup>1</sup> have suggested antibody activity.

In our experiments, we have inoculated suckling mice *i. p.* with metacyclic trypomastigotes of *T. rangeli* harvested from a modified LIT medium. This is in accord with recommendations by WHO<sup>30</sup> for inducing the multiplication of strains of trypanosomes in the laboratory by the use of susceptible hosts, particularly suckling mice, and different culture media.

Although *T. rangeli* has generally been considered to be non-pathogenic for vertebrate hosts<sup>5</sup>, the observation of tissue multiplication described above allows speculation on possible tissue alterations by the strain used by us, under certain conditions HOARE<sup>15</sup> has suggested that *T. rangeli* is a complex of strains, and DEANE<sup>6</sup> postulates that these may be evolving toward tissue multiplication. The major incidence of this trypanosomiasis is in children<sup>25,27</sup>, and it may be that very young children, infected with particular strains of *T. rangeli* would show invasion and damage in the heart and other organs. HERNANDEZ DE PAREDES y PAREDES<sup>14</sup> and De LEON<sup>8,9,10</sup> had suspected that pathological manifestations in humans (particularly children) might have been due to *T. rangeli*, which in some cases<sup>9</sup> was the only infective organism detected. TORREALBA<sup>23,24,25</sup> and TORREALBA, PIFANO and ROMER<sup>26</sup> also noted the exclusive presence of *T. rangeli* (*T. cruzi* being absent) in Venezuelan children showing clinical abnormalities (fever, edema, micropolyadenitis, high lymphocy-

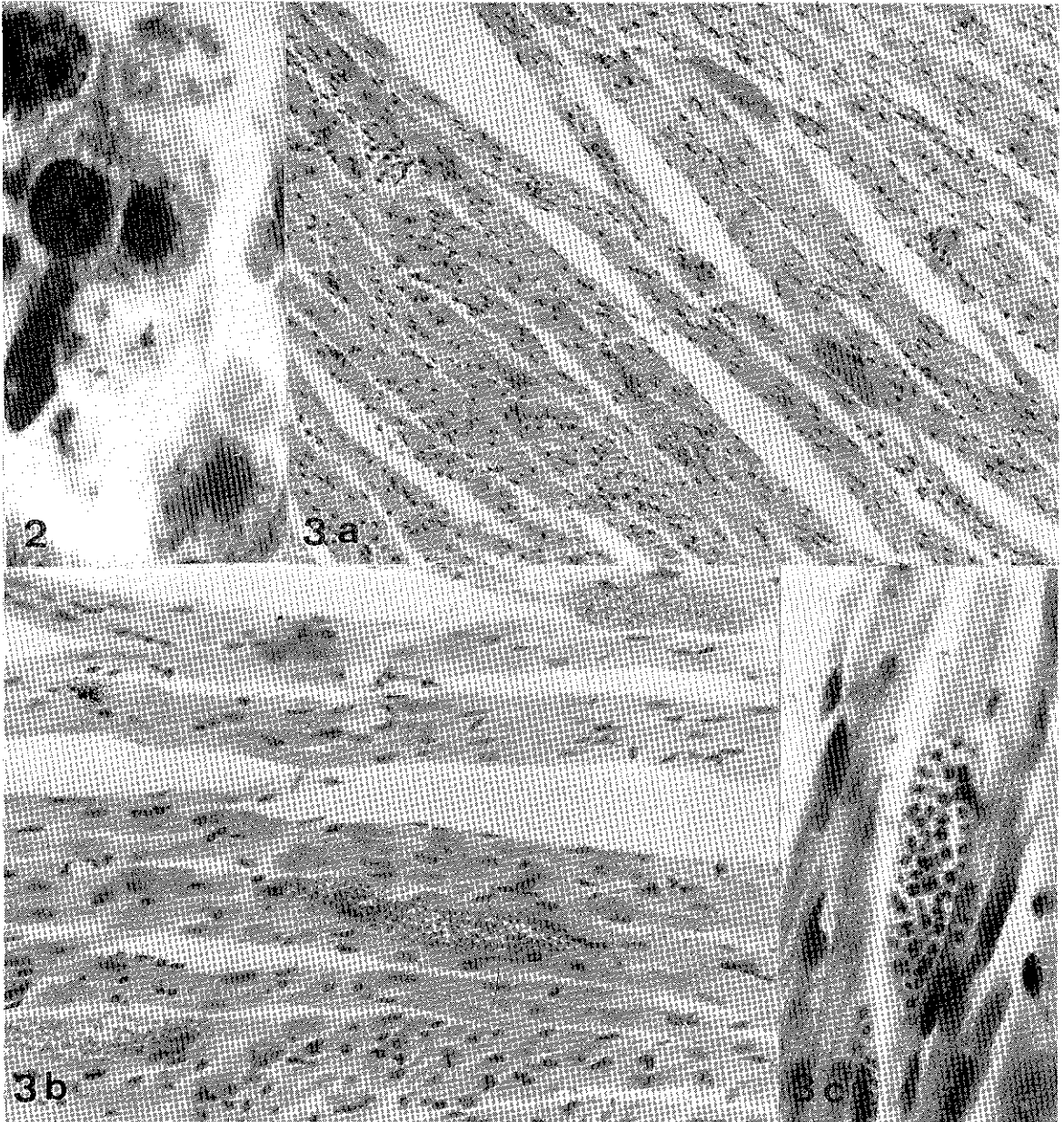


Fig. 2-3 — Histological sections from albino mice inoculated i.p. with metatrypomastigotes of *Trypanosoma rangeli* from LIT culture.

2 — Amastigotes in sinusoids of liver. 48 hr post-inoculation (1400 X)

3 — Section of heart. 72 hr post-inoculation.

a & b. General views showing location of nests of amastigotes and trypomastigotes in myocardial cells (140 X, 560 X)

c. Enlarged view of a nest containing amastigotes (950 X)

tosis, and occasionally hepatosplenomegaly) characteristic of infectious disease. However, PIFANO<sup>19</sup> reported that certain cases, originally attributed to *T. rangeli*, showed associated infections with *T. cruzi* on later examina-

tion. This same author and also MAEKELT<sup>16</sup> found no clinical, electrocardiographic, or haematological abnormalities in human cases of *T. rangeli*.

PIFANO<sup>20</sup>, although stating that no pathogenic symptoms were found in 842 cases of *T. rangeli* infections he studied, noted that in 224 cases of established *T. rangeli* infection, infection, electrocardiograms showed discrete myocardial damage in 6.7%. In an epidemiological survey of rural areas in Venezuela endemic for Chagas' disease, the control group of 5251 persons negative both xenodiagnostically and immunologically for *T. cruzi* showed a very nearly equal percentage of electrocardiographically detectable damage to the heart.

HERBIG SANDREUTER<sup>13</sup> found no histopathological changes in 130 white mice and two monkeys inoculated s.c. with culture forms of *T. rangeli*, concluding that the parasite is of little importance as a human pathogen.

TONN<sup>22</sup> has questioned whether *T. rangeli* might modify the pathology due to *T. cruzi* in mixed infections or whether the pathological picture is a separate entity. ZELEDON<sup>32</sup> has speculated on the possible effects of repeated exposure to *T. rangeli* antigens (brought about by the bites of infected triatomids) upon the development of pathology in mixed cases. GUHL and MARINKELLE<sup>12</sup> suggest that frequent reinfections in areas endemic for *T. rangeli* may result in antibody titers high enough to be mistaken for *T. cruzi*. GROGL and KUHN<sup>11</sup> state that the influence of concurrent or sequential *T. rangeli* infections on the pathogenesis of Chagas' disease has not been established.

The frequent finding of mixed infections of *T. cruzi* and *T. rangeli* in areas endemic for Chagas' disease<sup>5</sup>, plus the crossed serum reactions between the two parasites observed by ANTHONY et al.<sup>2</sup>, GUHL and MARINKELLE<sup>12</sup> and SCHECHTER et al.<sup>21</sup>, together with the observations described in the present paper, underline the necessity for further study of the immunobiology of *T. rangeli* in the mammal host, above all with an open mind.

### RESUMEN

*Trypanosoma (Herpetosoma) rangeli* Tejera, 1920: nota prévia sobre a histopatologia em camundongos infectados experimentalmente

Ratones machos (cepa NMRI) de 3 y 5 gr, inoculados i.p. con  $8 \times 10^6$  y  $9 \times 10^4$  metatripo-

mastigotes/gr cosechados de cultivo LIT de 12 días de repique de la cepa "Perro-82" de *Trypanosoma rangeli* fueron procesados, em determinados periodos postinoculación, para seccionar y teñir con hematoxilina-eosina y Giemsa-colofonio trozos de corazón, hígado, bazo, pulmones, fémur, riñón, intestino, estómago, cerebro, cerebelo, esternón y columna vertebral.

Se detallan los resultados preliminares sobre la histopatología provocada por el *T. rangeli* en los cinco primeros órganos citados. Los tejidos conjuntivos subcutáneo, periosteal, intersticial y peribronquial, así como las miocélulas del corazón fueron altamente parasitados por amastigotes y tripomastigotes.

Se discuten las posibles razones de la disminución del parasitismo tisular cuando la parasitemia se encontró en sus niveles máximos, así como la escasa inflamación obtenida en los tejidos parasitados.

Las observaciones de varios autores sobre el comportamiento del protozoario en humanos y en animales de laboratorio así como los resultados descritos en este trabajo, plantean la posibilidad de que determinadas cepas de *T. rangeli*, en condiciones particulares, podrían causar alteraciones patológicas en el mamífero.

### ACKNOWLEDGEMENTS

The authors wish to thank Mr. Ian McLure for assistance, both technical and in preparing the manuscript, and for the English translation. Mrs. Carmen E. Bermudez and Mr. J. V. Scorza for histological preparations; the Consejo de Desarrollo Científico y Humanístico de la Universidad Central de Venezuela (Project No. C 05.4/81) for financial support. Special thanks are due to Dr. Nestor Añez (Universidad de Los Andes, Venezuela) for supplying us with the strain of the parasite.

### REFERENCES

1. ANEZ, N.; VELANDIA, J. & RODRIGUEZ, A. M. — Estudios sobre *Trypanosoma rangeli* Tejera, 1920. VIII Respuesta a las reinfecciones en dos mamíferos. *Mem. Inst. Osw. Cruz.*, 80: 149-153, 1985.
2. ANTHONY, R. L.; CODY, T. S. & CONSTANTINE, N. T. — Antigenic differentiation of *Trypanosoma cruzi* and *Trypanosoma rangeli* by means of monoclonal-hybridoma antibodies. *Amer. J. trop. Med. Hyg.*, 30: 192-1197, 1981.

3. BRAY, R. S. & GARNHAM, P. C. C. — The Giemsa-Colophonium method for staining protozoa in tissue sections. *Indian J. Malar.*, 16: 153-155, 1962.
4. BRENER, Z. — Contribuição ao estudo da terapêutica experimental da doença de Chagas. Belo Horizonte, 1961. (Tese de Docência-livre — Faculdade de Odontologia e Farmácia da Universidade de Minas Gerais).
5. D'ALESSANDRO, A. — Biology of *Trypanosoma (Herpetosoma) rangeli* Tejera, 1920. In: LUMSDEN, W. H. R. & EVANS, D. A., ed. — *Biology of the kinetoplastida*. London, Academic Press, 1976. v. 1, cap. 8., p. 328-403.
6. DEANE, M. P. — On the life cycle of Trypanosomes of the lewisii group and their relationships to other mammalian trypanosomes. *Rev. Inst. Med. trop. S. Paulo*, 11: 34-43, 1969.
7. DE LEON, J. R. — Nota preliminar acerca de la enfermedad de Chagas en Guatemala. Casos encontrados en el Oriente de la Republica y probable existencia de un nuevo tripanosoma humana. *Rev. Cruz Roja Guatem.*, 9: 131-132, 1942 (cited by D'Alessandro, 1976).
8. DE LEON, J. R. — El *Trypanosoma rangeli* observado en seres humanos en Guatemala. *Publ. Inst. Invest. cient. (Guatemala)*, No. 3, 1949.
9. DE LEON, J. R. — Un nuevo foco de Tripanosomiasis humana por el *Trypanosoma rangeli* descubierto en Guatemala. *Publ. Inst. Invest. cient. (Guatemala)*, No. 4, 1950.
10. DE LEON, J. R. — Nueva encuesta sobre la Tripanosomiasis humana por el *Trypanosoma rangeli* en Guatemala. *Publ. Inst. Invest. cient. (Guatemala)*, No. 8, 1952.
11. GROGL, M. & KUHN, R. E. — Identification of antigens of culture forms of *Trypanosoma cruzi* and *Trypanosoma rangeli* recognized by sera from patients with chronic Chagas' disease. *J. Parasit.*, 70: 822-824, 1984.
12. GUHL, F. & MARINKELLE, C. J. — Antibodies against *Trypanosoma cruzi* in mice infected with *Trypanosoma rangeli*. *Aan. trop. Med. Parasit.*, 76: 361, 1982.
13. HERBIG-SANDREUTER, A. — Further studies on *Trypanosoma rangeli* Tejera, 1920. *Acta trop. (Basel)*, 14: 193-207, 1957.
14. HERNANDEZ DE PAREDES, C. & PAREDES, M. R. — Un caso de infección humana por *Trypanosoma rangeli*. *Rev. Fac. Med. (Bogotá)*, 18: 343-375, 1949. (cited by Zeledon, 1954).
15. HOARE, C. A. — Morphological and taxonomic studies on mammalian trypanosomes: I. The systematic position of *Trypanosoma rangeli*. In: ANSELM, A., ed. — *Medicina tropical*. Mexico, Editorial Fournier, 1968. p. 276-290.
16. MAEKELT, G. A. — Evaluación estadística de los resultados de encuestas epidemiológicas realizadas en Venezuela respecto a la etiología chagásica de las miocardiopatías crónicas rurales. *Arch. venez. Med. trop.*, 5: 107-115, 1973.
17. MILES, M. A.; ARIAS, J. R.; VALENTE, S. A.; NAUFF, R. D.; DE SOUZA, A. A.; POVOA, M. M.; LIMA, J. A. & CEDILLOS, R. A. — Vertebrate hosts and vectors of *Trypanosoma rangeli* in the Amazon basin of Brazil. *Amer. J. trop. Med. Hyg.*, 32: 1251-1259, 1983.
18. PAN, S. C. — *Trypanosoma cruzi*: Ultrastructure of morphogenesis in vitro and in vivo. *Exp. Parasit.*, 46: 92-107, 1978.
19. PIFANO, F. — Nueva tripanosomiasis humana de la región neotropical producida por el *Trypanosoma rangeli*, con especial referencia a Venezuela. *Arch. venez. Pat. trop.*, 2: 89-120, 1954.
20. PIFANO, F. — El estado actual de la Tripanosomiasis rangeli en Venezuela. *Arch. venez. Med. trop.*, 5: 185-192, 1973.
21. SCHECHTER, M.; FLINT, J. E.; VOLLER, A.; GUHL, F.; MARINKELLE, C. J. & MILES, M. A. — Purified *Trypanosoma cruzi* specific glycoprotein for discriminative serological diagnosis of South American tripanosomiasis (Chagas' Disease). *Lancet*, 2: 939-944, 1983.
22. TONN, R. J. — In: ZELEDON (1974, p. 83).
23. TORREALBA, J. F. — Una pequeña nota sobre el primer caso agudo de tripanosomiasis rangeli comprobado en Venezuela. *Gac. méd. Caracas*, 58: 51-57, 1950.
24. TORREALBA, J. F. — Otra pequeña nota sobre las tripanosomiasis en San Juan de los Morros, Estado Guárico, Venezuela. Cinco casos más de tripanosomiasis rangeli. "Tripanosomiasis de Tejera". Cuatro casos agudos de Enfermedad de Chagas. Un caso mixto agudo. *Gac. méd. Caracas*, 58: 148-156, 1950.
25. TORREALBA, J. F.; MORENO, J.; DIAZ VASQUEZ, A. & RAMOS, I. — Enfermedad de Chagas y Tripanosomiasis de Tejera. In: TORREALBA, J. F. — *Investigaciones sobre la Enfermedad de Chagas en San Juan de los Morros, Estado Guárico, Venezuela*. Otras Notas Científicas. Recopilación. Fascículo V. Caracas, Imprenta Nacional, 1956. p. 35-65.
26. TORREALBA, J. F.; PIFANO, F. & ROMER, M. — Investigaciones sobre Enfermedad de Chagas y Tripanosomiasis rangeli en el Distrito Roscio, Estado Guárico, Venezuela. *Gac. méd. Caracas*, 58: 85-98, 1950.
27. TORRES, R. A. — *Trypanosoma rangeli* (Tejera, 1920) en la Guajira venezolana. Estudio del parásito en el humano. *Kasmera*, 7: 41-63, 1979.
28. URDANETA-MORALES, S. & TEJERO, F. — *Trypanosoma (Herpetosoma) rangeli* Tejera 1920: Mouse model for high, sustained parasitemia. *J. Parasit.*, 71: 409-414, 1985.
29. URDANETA-MORALES, S. & TEJERO, F. — *Trypanosoma (Herpetosoma) rangeli* Tejera, 1920: Intra-

- cellular amastigote stages of reproduction in white mice. *Rev. Inst. Med. trop. S. Paulo*, 28: 166-169, 1986.
30. WHO Report Second Meeting Imm. Comp. Sc. Work. Group Chagas' Dis. UNDP/WHO Sp. Prog. Res. Training Trop. Dis., 1980.
31. ZELEDON, R. — *Tripanosomiasis rangeli*. *Rev. Biol. trop. (S. José)*, 2: 231-268, 1954.
32. ZELEDON, R. — Epidemiology, modes of transmission and reservoir hosts of Chagas' disease. In: *TRYPANOSOMIASIS AND LEISHMANIASIS WITH SPECIAL REFERENCE TO CHAGAS' DISEASE*. Amsterdam, Elsevier, 1974. p. 51-85. (Ciba Foundation Symposium 20 — new series).

---

Recebido para publicação em 23/10/1985.