

## OPPORTUNISTIC FUNGAL ENDOCARDITIS FOLLOWING AORTIC VALVE REPLACEMENT

### A case report

Tito CAVALLO<sup>(1)</sup>, Bernardo LICHEWITZ<sup>(1)</sup> and Katalin ARVAI<sup>(2)</sup>

#### SUMMARY

Case report of fungal endocarditis following aortic valve replacement with Starr-Edwards prosthesis. At necropsy, the orifice of the prosthetic valve was almost completely occluded by a fungal thrombus. The progressive development of the microorganism resulted in a complete immobilization of the ball of the prosthetic valve. The fungal vegetation involved the prosthesis almost entirely and was a fragile and easily breakable mass. Multiple emboli detached from the fungal thrombus and occluded several vessels, mainly in the brain, kidneys, intestine and left lower extremity. The etiologic agent was found only at necropsy. It is, probably, *Penicillium* or *Hormodendrum* which must be considered an extremely rare microorganism capable of producing endocarditis.

#### INTRODUCTION

The stenotic and regurgitant lesions of the cardiac valves could effectively be corrected after the introduction of the Starr-Edwards prosthesis. STARR et al.<sup>13</sup>, in 1962, had 3 deaths due to staphylococcal septicemia among 16 patients treated with a ball-valve prosthesis. They assumed then that the insertion of prosthetic material within the heart facilitates infection, thrombosis and embolism.

TEIXEIRA<sup>15</sup>, reviewing 1,668 cases submitted to cardiac surgery with extracorporeal circulation, found infection as a cause of death in 4.5 per cent of the patients.

*Staphylococcus*<sup>1, 2, 4, 5, 11, 12, 14</sup> has been the most common microorganism found in cases of endocarditis. However, *Streptococcus*<sup>4</sup> *Salmonella*<sup>16</sup>, *Pseudomonas*<sup>4, 10</sup> and *Escherichia*<sup>4</sup> have also been observed, though less

frequently. Fungal endocarditis following cardiac surgery is a very rare event being *Candida*<sup>8, 12</sup> and *Aspergillus*<sup>18</sup> the fungi more commonly identified.

#### CASE REPORT

A 22 year-old white woman with aortic regurgitation had her aortic valve replaced with a Starr-Edwards prosthesis in March, 1966. Three and six months later she was readmitted with fever, and in both occasions blood cultures were negative. One month before death she presented a clinical picture of peripheral arterial embolism and headache.

*Necropsy findings: Heart* — weighed 320 g, was enlarged and globe shaped. There was complete adhesion of the pericardium, which appeared as a white fibrous membrane of 2

(1) Instructor of Pathology (Departamento de Anatomia e Fisiologia Patológicas da Faculdade de Medicina da Universidade de São Paulo, Brasil). Head: Prof. Dr. Constantino Mignone

(2) Medical student

to 3 mm in thickness. There was little enlargement of the atria and right ventricle. The left atrium was covered with a white thickened endocardium. There was moderate enlargement and hypertrophy of the left ventricle and diffuse thickening of the mitral leaflets and of its chordae tendinae, the latter appearing also shortened. Old surgical scars were seen on the anterior aspect of the right atrium and on the anterior wall of the ascending aorta. The aortic valve was replaced with a Starr-Edwards prosthesis. The prosthesis was almost entirely covered with brown-red vegetations containing numerous easily breakable verrucous formations, which completely immobilized the ball of the valve. On the central part of the prosthesis there was an orifice 4 mm in diameter, through which the blood flow was maintained, but the vegetations filled the space between the metallic ring and the surrounding tissue, leaving small clefts occupied with granulous masses.

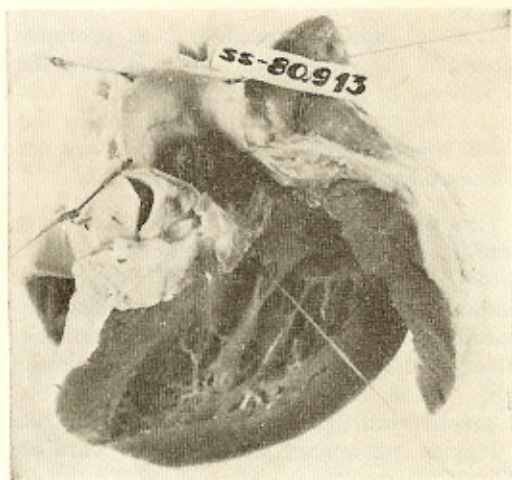


Fig. 1 — Heart — Infectious endocarditis of the Starr-Edwards prosthesis. See the prosthesis covered by a dark material

The microscopic picture showed, around the prosthesis, a dense, partially hyalinized fibrous tissue with histiocytes and marked infiltration with polymorphs, some of which degenerated. The periphery of this area contained fibrin, tissue debris and fungi. The vegetations covering the prosthesis were made up of fibrin, erythrocytes and polymorphs around fungous colonies. These had branchless septated hyphae devoided of capsule

or vesicle, but surrounded by numerous round shaped fuliginous conidial-like structures. In H.E. stain the microorganisms were yellow-brownish and their cross sections were

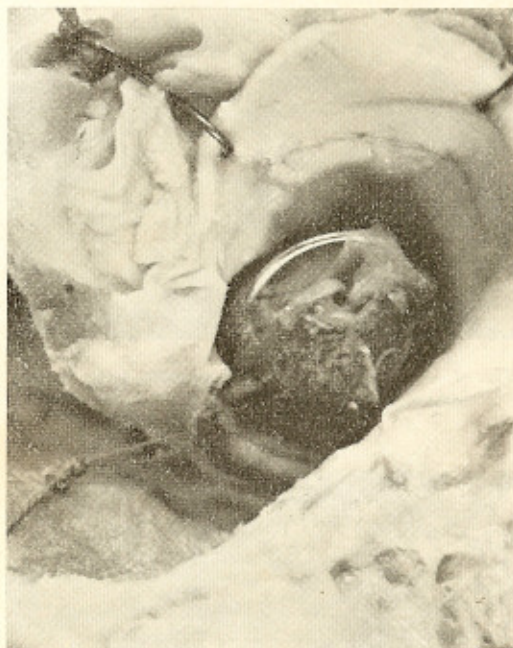

Fig. 2 — Heart — Aortic view of the Starr-Edwards prosthesis. Note the small orifice left by the thrombotic vegetation

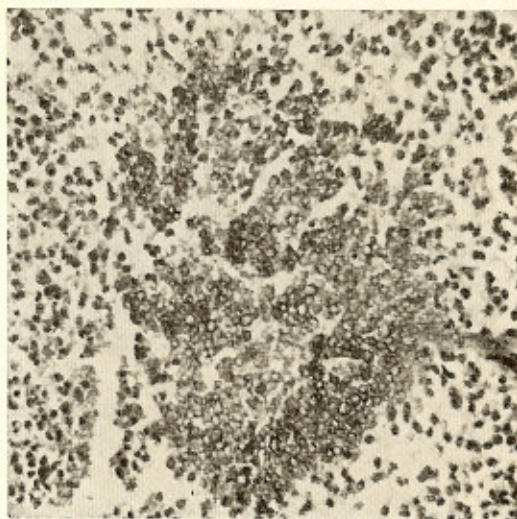


Fig. 3 — Fungal colonies in the material removed from the aortic prosthesis. Note also the surrounding inflammatory infiltration (P.A.S. — 16 X)



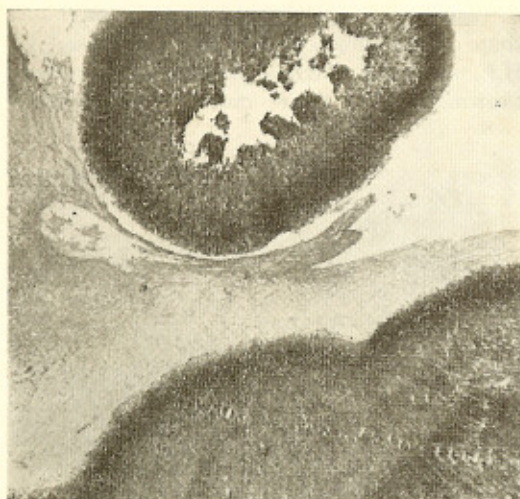

Fig. 4 — Brain — Fungal colonies with scanty inflammatory reaction (P.A.S. — 16 X)

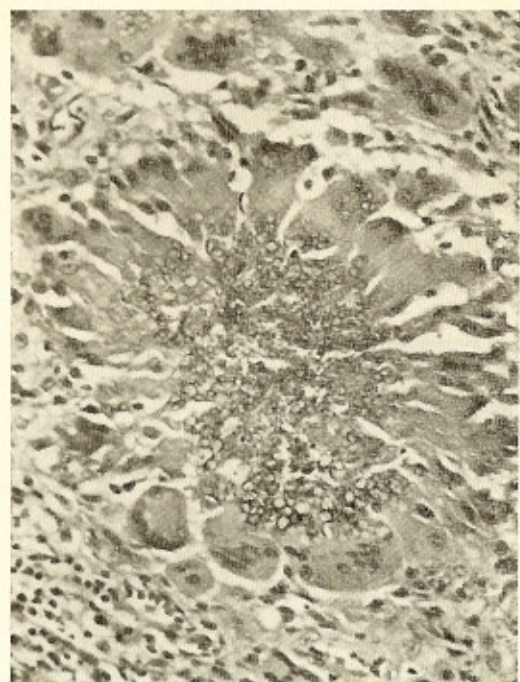


Fig. 5 — Wall of the femoral artery — Granulomatous pattern with multinucleated giant cells containing phagocytized fungi (P.A.S. — 40 X)

rounded. On morphological basis, they were considered to be fungi of *Penicillium* or *Hor-modendrum* genus<sup>9</sup>. *Diagnosis*: Cardiac enlargement. Healed adhesive pericarditis. Old

surgical scars on the right atrium and ascending aorta. Replacement of the aortic valve with a Starr-Edwards prosthesis. Infectious endocarditis of the Starr-Edwards prosthesis with a fungal component. Healed rheumatic endocarditis of the mitral valve.

The other important anatomic diagnosis were: recent focal ischemic infarction of the right parietal lobe; organizing infarction of the right thalamus; fungal embolism of the branches of the right medial cerebral artery; fungal thromboarteritis of embolic origin (fungal embolus from the heart) of the femoral superficial artery; recent infarctions in both kidneys due to fungal arterial embolism; recent infarction of the spleen; partial occlusion of the superior mesenteric artery by a fungal embolus; ischemic lesions of the left leg.

#### COMMENTS

The anatomic lesions found at necropsy explained the clinical picture. Despite the hypothesis of bacterial endocarditis, it was impossible to identify any bacterium in the blood stream and the fungal origin was not considered in the differential diagnosis.

The pathologic alterations of the heart were like those described by others<sup>5, 11, 12, 14</sup>. Bacterial or fungal endocarditis may be followed by the formation of a thrombus covering partially or entirely the prosthetic valve<sup>3</sup> and by immobilization of the plastic ball. As a consequence, there will be a progressive impairment of the cardiac output and acute pulmonary edema<sup>4, 5</sup> or cardiac failure will result.

The most common site of infection is the cardiac tissue surrounding the metallic ring of insertion of the prosthesis<sup>13</sup>, where microabscesses develop<sup>11</sup>, causing detachment regurgitation will follow. When the detachment of the valve<sup>4</sup>. A variable degree of aortic is complete<sup>1, 4</sup>, the prosthesis may migrate within the aorta with impactation in the aortic arch. This complication should be remembered when to the clinical picture are added arterial hypotension, loss of peripheral pulse and a diastolic heart murmur<sup>4</sup>.

Generally, it is accepted that the insertion of a foreign material within the heart facili-

tates infection, thrombosis and embolism<sup>8, 13, 14</sup>. Among predisposing factors are trauma, infectious focus, leukocytic dysfunction following extracorporeal surgery and, mainly, prolonged therapeutic with broad spectrum antibiotics and adrenal cortical hormones<sup>6, 7, 8, 14</sup>. Indeed, the surgery offers the portal of entry as well as the damaged surface to the fixation and development of the microorganism<sup>12</sup>.

The normal process of reparation covers the prosthetic ring with collagen tissue and endothelium, which prevents bacterial infection<sup>14</sup>. When endocarditis appears soon after surgery, it is most probably due to bacterium, but when it occurs later, fungal infection must be suspected<sup>8</sup>.

The term opportunistic fungus was suggested by Utz<sup>17</sup> to qualify pathogenic or non-pathogenic fungi "which adapt themselves to make profitable use of the circumstances of the moment".

In the present case, surgery, by the insertion of the aortic prosthesis, was the essential factor to the development of the picture. It is probable that in the early stage of the disease this patient has had a bacterial endocarditis which was cured by antibiotics. Nevertheless, this probably facilitated the development of the fungus as well as its dissemination, and we believe that the term opportunistic fungus can here be applied.

#### RESUMO

#### *Endocardite por fungo oportunista em prótese da valva aórtica. Registro de um caso*

Os Autores publicam caso de endocardite micótica implantada sobre prótese de Starr-Edwards que substituíra a valva aórtica. O fungo, pela sua multiplicação, recobriu quase completamente a prótese deixando apenas pequeno pertuito de 0,4 cm por onde se fazia o fluxo. Seu crescimento para o interior dos arcos metálicos produziu imobilização da bola plástica. A vegetação micótica friável, por desprendimento, deu origem à formação de êmbolos micóticos que ocluíram vasos cerebrais, renais, mesentérica superior e femoral superficial. A etiologia micótica só pôde ser confirmada na necropsia. O agente, *Penicillium* ou *Hormodendrum*, deve ser considerado fungo oportunista de rara incidência nesse tipo de afecção.

#### REFERENCES

1. BABA, N. & MCKISSICK, T. L. — Mycotic false aneurysm of the aorta following aortic valvular prosthesis: a case report. *Circulation* 31:575-578, 1965.
2. CALLAGHAN, J. C. — Replacement of the aortic and mitral valves using the Starr-Edwards ball-valve prosthesis. *Canad. Med. Ass. J.* 91:411-421, 1964.
3. Case records of the Massachusetts General Hospital: Case 16, 1967. *New Eng. J. Med.* 276:857-866, 1967.
4. COHN, L. H. et alii — Bacterial endocarditis following aortic valve replacement: clinical and pathologic correlations. *Circulation* 33: 209-217, 1966.
5. COLVIN, O. M.; WALDMAN, R. H. & LEE, S. — Staphylococcal infection of a Starr-Edwards prosthesis, with fatal obstruction of the mitral valve. *New Eng. J. Med.* 273: 1380-1381, 1965.
6. DILLON, M. L. & SEALY, W. C. — Surgical aspects of opportunistic fungus infections. *Lab. Invest.* 11 (pt. 2):1231-1236, 1962.
7. FRENKEL, J. K. — Role of corticosteroids as predisposing factors in fungal diseases. *Lab. Invest.* 11 (pt. 2):1192-1208, 1962.
8. JAMSHIDI, A.; POPE, R. H. & FRIEDMAN, N. H. — Fungal endocarditis complicating cardiac surgery. *Arch. Intern. Med.* (Chicago) 112:370-376, 1963.
9. LACAZ, C. da S. — *Manual de Micologia Médica*. 2.<sup>a</sup> Edição São Paulo, Irmãos Dupont, 1956, pp. 7-11.
10. LITTLEFIELD, J. B.; MULLER Jr., W. H. & DAMMANN Jr., J. F. — Successful treatment of *Pseudomonas aeruginosa* septicemia following total aortic valve replacement. *Circulation* 31: (Suppl. 1), 103-107, 1965.
11. ROBERTS, W. C. & MORROW, A. G. — Bacterial endocarditis involving prosthetic mitral valve. *Arch. Path.* 82:164-169, 1966.
12. SIMMONS, N. A. & TURNER, P. — *Candida* endocarditis after cardiac surgery. *Brit. Med. J.* 2:1041-1042, 1963.
13. STARR, A.; EDWARDS, M. L. & GRISWOLD, H. — Mitral replacement: late results with a ball valve prosthesis. *Progr. Cardiovasc. Dis.* 5:298-312, 1962.
14. STEIN, P. D.; HARKEN, D. E. & DEXTER, L. — The nature and prevention of prosthetic valve endocarditis. *Amer. Heart J.* 71:393-407, 1966.

15. TEIXEIRA, J. — A study of major causes of death following cardiac surgery with extracorporeal circulation (analysis of 1,668 operations performed in Brazil). *Rev. Brasil. Cir.* 46:379-381, 1963.
16. TILLOTSON, J. R. & LERNER, A. M. — Mycotic aneurysm and endocarditis. Two uncommon complications of *Salmonella* infection in the same patient. *Amer. J. Cardiol.* 18:267-274, 1966.
17. UTZ, J. P. — The spectrum of opportunistic fungus infections. *Lab. Invest.* 11 (pt. 2): 1018-1025, 1962.
18. WATTS, L. E. et alii — Clinical experience with mitral and aortic valve prosthesis. *Southern Med. J.* 59:1287-1291, 1966.

---

Recebido para publicação em 9/4/1968.