

## TRICHOPHYTON SIMII. ITS OCCURRENCE IN BRAZIL

A. T. LONDERO (1) and Jeni P. BENEVENGA (2)

### SUMMARY

The first autochthonous case of human infection by *T. simii* occurring in Brazil was thus reported. The origin of the infection could not be traced.

### INTRODUCTION

PINOY<sup>6,7</sup>, in 1912, described a fungus isolated from a monkey's lesions and named it *Epidermophyton simii*. STOCKDALE et al.<sup>10</sup>, in 1965, redescribed this organism as *Trichophyton simii* and described its perfect form as *Arthroderma simii*. This fungus has been isolated from naturally infected monkeys<sup>1,6,10</sup>, poultry<sup>9</sup> and dogs<sup>5</sup>. Autochthonous human infections by *T. simii* has been reported in India<sup>2,3,5</sup>.

The present report deals with an autochthonous human case of *T. simii* infection diagnosed in Rio Grande do Sul, Brazil.

### CASE REPORT

**History:** A 20-year-old-white girl presented an erythematous plaque-like lesion on her thigh. The lesion had ill defined lateral and inferior borders; its superior border was well defined by small crusts and vesicles. The lesion was scattered with multiple little nular elevations, some crusted. There was no pruritus (Fig. 1).

**Laboratory findings:** Scrapings were taken for direct examination and culture. The direct mount was positive for dermatophytic elements. The culture on Mycosel agar (BBL) rapidly grew up as flat and rather thin colony that reached 4 cm in one week, at room temperature. Subcultures on Sabouraud dex-

trose agar were also rapidly growing. They presented a flat beige-colored surface with a central white umbo; their texture was velvety in their central portion, becoming powdery to the periphery (Fig. 2). The under-surface was vinaceous in its central area. Microscopic examination showed an enormous number of macroconidia (Figs. 3 to 9). These were hyaline, smooth walled and fusiform with up to 10 septa (6-10 x 30-100  $\mu$ ). Soon chlamydospores began to be formed in the macroconidia. Microconidia (2-3x3-6 $\mu$ ) were rare in young culture, but became numerous in old ones. They were pyriform and born in thyrses along the hyphae (Figs. 4 and 9). Spiral hyphae were also seen.

### EPIDEMIOLOGICAL INVESTIGATION

The patient was seen in January, 10, 1972. She lived in a farm near Santa Maria, Rio Grande do Sul, with her parents and nine siblings. The farm had 4 cats, 4 dogs, 11 pigs and 30 chickens around the house. There were also 2 horses and 12 dairy cows with their calves. The farm was located far from a forest area.

All member of the family were screened for dermatophytosis. Only a 16-year-old boy presented a ringworm lesion, which proved to be a *Microsporum nanum* infection. All the animals of the farm were examined for suspected ringworm lesion. No animals presented lesion. Hairs were collected from the

From the Department of Pathology (Section Mycology), Federal University of Santa Maria, 97100 Santa Maria, Rio Grande do Sul, Brasil

(1) Bolsista do Conselho Nacional de Pesquisas (CNPq)

(2) Auxiliar de ensino

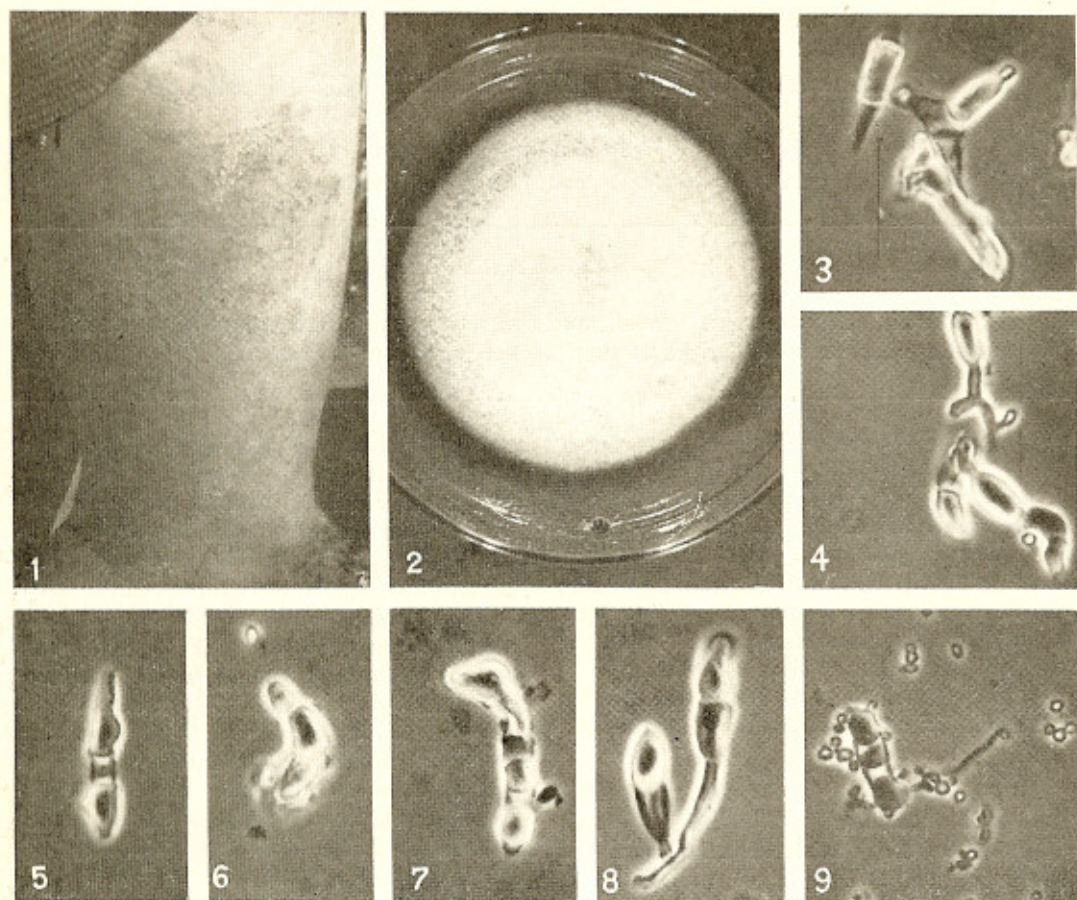


Fig. 1 — Lesion on the patient's thigh.  
Fig. 2 — *T. simii* on Sabouraud's medium after 2 weeks, at room temperature.  
Figs. 3 - 9 — Macroconidia of *T. simii*, some presenting endochlamydospores.  
Figs. 4 and 9 — Microconidia can also be seen.

head and shoulders of 3 pigs, 4 dogs and 4 cats. They were cultured on triplicate slopes of Mycosel agar (BBL). Only one strain of the *Microsporium gypseum* complex was isolated from a dog.

Twenty soil samples were collected from a 1/4-acre pig lot and another equal number of samples were taken from the court-yard. They were assayed in duplicate, using human and dog's hair bait<sup>13</sup>. In almost all plates a heavy overgrowth of *M. gypseum* complex was obtained from the soil collected from the pig lot. *Trichophyton ajelloi*, *Microsporium cookei* and other keratinophilic fungi were also isolated. From the court-yard soil, all but *M. cookei* were isolated.

#### DISCUSSION

*T. simii* is a zoophilic dermatophyte primarily parasite of monkeys and poultry. Human infection by this dermatophyte is relatively common in India. Outside of this country only three human cases of *T. simii* infection have been diagnosed: RIPPON et al.<sup>3</sup> patient probably acquired his infection when in India; one of MACKENZIE & RUSK's<sup>4</sup> patients had been infected handling laboratory animals infected by *T. simii* and the second patient had an origin of his infection which could not be traced.

Our patient lived all her life on a farm far from a forest region. No domestic animals

were found to be infected by dermatophytes, neither was the girl known to have handle pet monkeys. Notwithstanding, *T. simii* has not been isolated from soil in any region of the world, we assume that our patient acquired her infection from the soil, the natural reservoir of dermatophytes.

#### RESUMO

#### *Trichophyton simii*. Sua ocorrência no Brasil

É descrito o primeiro caso autóctone de infecção humana por *T. simii*, ocorrido no Brasil. A fonte de infecção não pôde ser evidenciada.

#### ACKNOWLEDGEMENT

We are greatly indebted to Dr. A. A. Padhye (Edmonton, Canada) for confirming the identification of our isolate and verifying that it mated with *Arthroderma simii* (—). We are grateful to Mrs. Neuza Martins Carson by the English correction of the manuscript and to Mr. Bondarenko for the patient and *T. simii* colony's photographs.

#### REFERENCES

1. EMMONS, C. W. — *Trichophyton mentagrophytes* (*Pinoella simii*) isolated from dermatophytosis in the monkey. *Mycopath. et Mycol. Appl.* 2:317-320, 1940.
2. GUGNANI, H. C.; MULAY, D. N. & MURTY, D. K. — Fungus flora of dermatophytosis and *Trichophyton simii* infection in North India. *Indian J. Derm. Venereol.* 33:73-82, 1967.

3. KLOKKE, A. H. & DURAIRAJ, P. — The casual agents of superficial mycoses isolated in rural areas of South India. *Sabouraudia* 5:153-158, 1967.
4. MACKENZIE, D. W. R. & RUSK, L. W. — The mycological diagnostic service: a five year survey (1959-1963). *Ulster Med. J.* 33: 94-100, 1964.
5. MOHAPATRA, L. N. & MAHAJAN, V. M. — *Trichophyton simii* infection in man and animals. *Mycopath. et Mycol. Appl.* 41:357-362, 1970.
6. PINOY, E. — *Epidermophyton* du singe. *Bull. Soc. Path. Exot.* 5:60-63, 1912.
7. PINOY, E. — Sur un teigne cutanée du singe. *Compt. Rend. Soc. Biol. (Paris)* 72: 59, 1912.
8. RIPPON, J. W.; ENG, A. & MALKISON, F. D. — *Trichophyton simii* infection in the United States. *Arch. Derm. (Chicago)* 98: 615-619, 1968.
9. SING, M. P. — *Studies on the occurrence of mycotic infections in domestic animals and poultry*. Thesis. Agra University, 1963.
10. STOCKDALE, P. M.; MACKENZIE, D. W. R. & AUSTWICK, P. K. C. — *Arthroderma simii* sp. nov., the perfect state of *Trichophyton simii* (Pinoy) comb. nov. *Sabouraudia* 4:112-123, 1965.
11. VANBREUSEGHEM, R. — Technique biologique pour l'isolement des dermatophytes du sol. *Ann. Soc. Belge Med. Trop.* 32:173-178 1952.

Recebido para publicação em 28/4/1972.