

EXPERIMENTAL INFECTION OF JORGE LÔBO'S DISEASE IN THE CHEEK-POUCH OF THE GOLDEN HAMSTER

(*MESOCRICETUS AURATUS*)

Mário Machado SAMPAIO⁽¹⁾ and Leônidas Braga DIAS⁽²⁾

SUMMARY

The aetiologic agent of Jorge Lôbo's disease inoculated into the cheek-pouch of 22 hamsters (*Mesocricetus auratus*) produced 1.5 to 5 mm diameter nodules composed of histiocytes and giant cells containing parasitic fungi. Subcutaneous infections of similar material into the legs and ears did not produce any lesions.

Fungal spores were present 180 days after being injected. Infected cheek-pouch material from a primary isolation was passaged twice in hamsters. The histopathology of the lesions produced in the donor and subinoculated hamsters was the same.

Tissue kept for 41 days in tissue culture fluid on the otherhand produced small lesions by 30 days. When examined 90 days later, however, no lesions were seen.

INTRODUCTION

Except for the results of BORELLI³ on a successful inoculation is *anima nobile* by the causal fungus of Jorge Lobo's disease and the accidental infection in man recorded by PORTO (AZUALY et al.¹) all attempts to establish the infection in laboratory animal have failed. This paper deals with experimental infections of Jorge Lobo's fungus in the cheek-pouch of the hamster. BILLIGHAM & SILVERS² showed that the connective tissue of hamster cheek-pouch showed little reaction to heterologous antigens. In our attempts to infect hamsters we, therefore, concentrated on this region in particular.

MATERIAL AND METHODS

Material for inoculation was obtained from biopsies of three patients with Jorge Lobo's disease interned in the Department of Der-

matology — Service of Professor Domingos Silva — of the "Universidade Federal do Pará, Brasil". Details of the cases are as follows:

Case 1 — A.C.M., white, male, 56 years old, farmer, who dates the onset of this disease 15 years ago. Extensive lesion of the left inferior member, including foot, leg and distal half of thigh, SILVA⁴.

Case 2 — S.M.N., melanodermic, male, 35 years old, farmer, who dates the onset of his disease about 20 years ago. Lesions on the dorsal side of the right hand with subcutaneous nodules of the hand and forearm and with epitrochlean lymph node (DIAS et al.⁴, for further details of this case).

Case 3 — J.A.S., melanodermic, male, 40 years old, farmer who dates the onset of the disease 10 years ago. Lesion on the dorsal side of the arms and sacral region (DIAS et al.⁴, for further details of this case).

(1) Departamento de Histologia e Embriologia da Faculdade de Medicina da Universidade Federal do Pará, Brazil

(2) Seção de Patologia do Instituto Evandro Chagas, da Fundação SESP, Belém, Pará, Brazil

All biopsies were divided in two pieces: one was immediately fixed in 10% formalin for microscopy; the other was kept in Rhodicilline Fenegan 1/4 (Penicillin G Procaïn 300,000 units, Penicillin G crystallin 100,000 units and Streptomycin sulfate 0.25 g per ml, plus prometazin chloride, RHODIA).

22 adult hamsters (*Mesocricetus auratus*) were used in this investigation. All animals, except numbers 1, 2, 3 and 4, were infected by implanting a small piece of biopsy material, about 1.5 mm to 2.0 mm in size, into the wall of the fundus of an everted cheek-pouch. The implantation was performed under general anaesthesia (ABBOTT Nembutal) with the help of a number 15 gauge needle. Hamsters 1, 2, 3 and 4 were injected in the same site with triturated biopsy material. On one occasion the pieces were kept for 5 days at 4°C in Rhodicilline Fenegan 1/4 before being inoculated.

Hamsters numbers 10 and 11 were inoculated in the right cheek-pouch with material that had been fixed for 135 days in 10% formalin and washed for 24 hrs in tap water, and in the left cheek-pouch with fragments kept for 41 days in tissue culture fluid (199 medium, Grand Island Biological Co., with 20% foetal bovine serum and with Yeastolate, DIFCO).

Biopsy material was also inoculated subcutaneously into the left leg of hamsters 12 and 13 and into both ears of hamsters 9, 12, 13 and 14 and the right ear of hamster 4.

RESULTS

A summary of the results of the above mentioned inoculations is given in the Tables I and II.

TABLE I

Results of experimental infections of hamster cheek-pouches with Jorge Lôbo's fungus obtained from natural infections in man and experimental infections in hamsters

Time of observation	Hamster no.	Results Cheek-pouch		Source of implant	Observations
		Right	Left		
6 days	16	+	+	Case 2	Kept in Rhodicilline for 5 days ca. 4°C
13 days	17	+	+	Case 2	Kept in Rhodicilline for 5 days ca. 4°C
20 days	15	+	-	Case 2	
30 days	1	0	-	Case 1 *	Parasites in lymph nodes of left side
30 days	2	0	+	Case 1 *	Parasites in lymph nodes of left side
30 days	12	+	+	Case 1	
32 days	6	+	+	Case 1	Parasites in lymph nodes of left side
32 days	9	+	+	Case 2	
34 days	20	+	+	Case 3	
44 days	13	+	-	Case 1	Parasites in lymph nodes of right side
59 days	3	0	+	Case 1 *	
61 days	4	+	0	Hamster 3	Parasites in lymph nodes of right side
73 days	21	+	+	Case 3	Inoculum from 59 day old infection
83 days	7	+	+	Case 1	Parasites in lymph nodes of right side
90 days	5	+	+	Hamster 4	Inoculum from 120 day old infection
101 days	8	+	+	Hamster 6	Inoculum from 32 day old infection
120 days	4	0	+	Case 1 *	
121 days	14	+	+	Case 1	
159 days	22	-	-	Case 3	
164 days	18	+	+	Case 2	Kept in Rhodicilline for 5 days ca. 4°C
182 days	19	+	+	Case 2	Kept in Rhodicilline for 5 days ca. 4°C

(0) = not inoculated

(*) = triturated material

TABLE II

Results of experimental infections of hamster cheek-pouches with Jorge Lobo's fungus which had previously been fixed or cultured

Hamster no.	Time of observation	Cheek-pouch	Result	Source of implant	Treatment
10	30 days	Right	-	Case 1	Formalin 10%
		Left	+	Case 2	199 medium
11	120 days	Right	-	Case 1	Formalin 10%
		Left	-	Case 2	199 medium.

The lesions observed 6 days after inoculation (Fig. 1 and 7) were exudative in character with a central necrotic region containing abundant neutrophils. The periphery of the lesion was encircled by histiocytes, and occasional eosinophils. The fungi were either free in the necrotic area or more rarely in histiocytes (Fig. 7). A nodule was visible after 13 days, with a zone of histiocytes and fibroblasts around the necrotic tissue but there was less leucocytic reaction. The histiocytes were conspicuous with clear, foamy cytoplasm containing frequent fungi (Fig. 8).

Figure 9 represents the aspect of the lesion 20 days after inoculation, where the giant cells are beginning to appear.

In animals examined 30 (Fig. 10) to 59 days after inoculation the lesions were basically nodules of giant cells encircled by a well established vascular bed. Occasional mononuclear cells, histiocytes, and fibroblasts were also seen. In two lesions there was minor infiltration of neutrophils, and the fungi were abundant in contrast with the lesions described above.

After 83 days or more the lesions were well developed nodules and fibroblast were rare. There was a well defined reticular trama around the lesion and there were individual giant cells containing fungi (Fig.

12). No leucocytic infiltration was noted and the capillary vessels were well developed. A few fat lobules were present, increasing progressively from 120 to 180 days after inoculation but did not at this stage interfere with the nodular appearance of the lesion (Figs. 2, 3, 4, 11, 12, 13 and 14). After 210 days, in the serial passaged material (left cheek-pouch of hamster 4, Figs. 3 and 4), the fat infiltration began to disrupt the nodule forming islands of giant cells containing fungi with occasional mast cells (Figs. 3 and 14).

No infections were noted in the hamsters inoculated subcutaneously except for cicatricial remnants in the ear of the hamster 9 (Fig. 5).

Granulomas in the satellite lymph nodes of the cheek-pouches with histiocytes containing fungi (Fig. 6) were found in 6 hamsters (Table I).

The biopsy material fixed in formalin did not infect hamster, whereas, the material incubated in tissue culture fluid produced lesions by 30 days that disappeared by 90 days.

The development and histopathology of the fungus in the experimental infections in hamsters was similar to the natural infections in man.

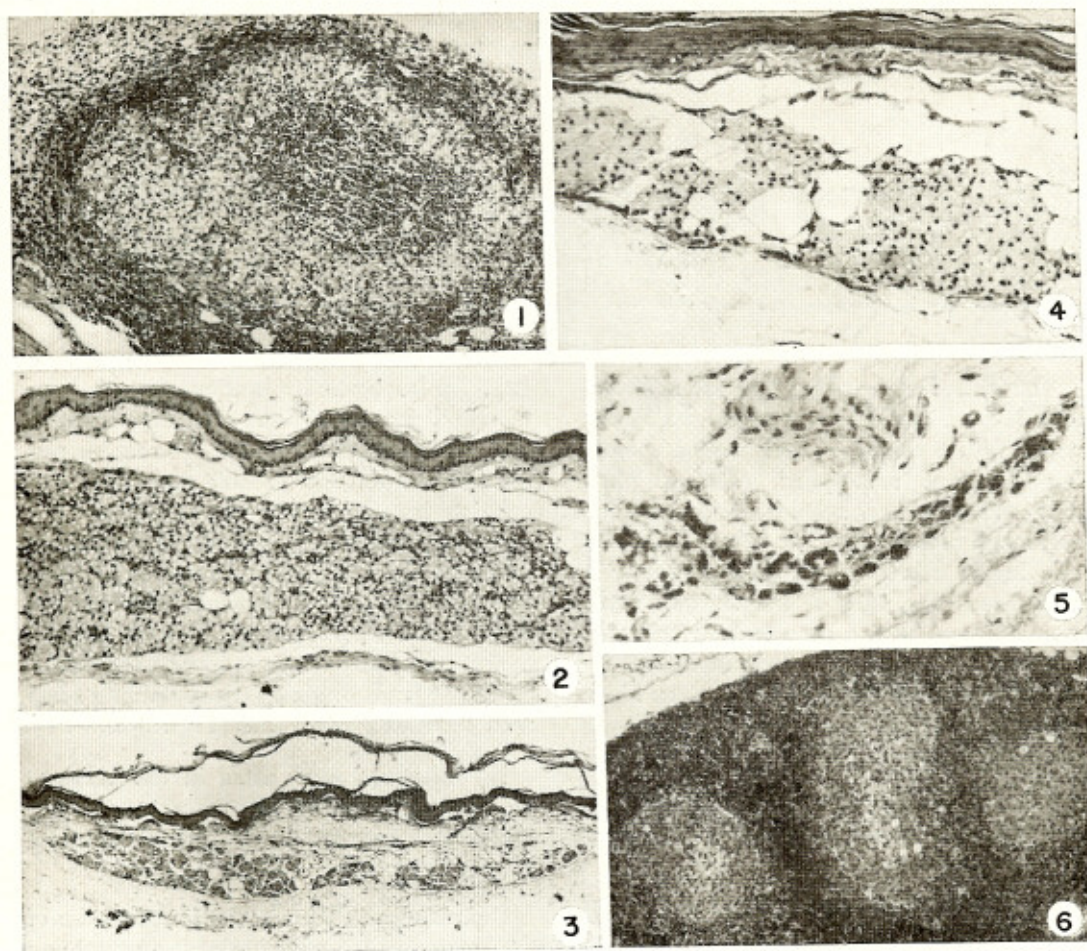


Plate 1 — Low power photomicrographs of experimental of Jorge Lóbo's disease produced in the cheek-pouch of Golden Hamster. (Stained in haematoxylin and eosin). Fig. 1 — 6 day old lesion (Hamster no. 16) 50,4 X. Fig. 2 — 121 day old lesion (Hamster no. 14) 75,6 X. Fig. 3 — 210 day old lesion (Hamster no. 5) 30 X. Fig. 4 — 182 day old lesion (Hamster no. 19) 75,6 X. Fig. 5 — 32 day old ear lesion showing cicatricial remnant (Hamster no. 9) 75,6 X. Fig. 6 — Granulomatous area in accessory lymph node of an 83 day old lesion (Hamster no. 7) 75,6 X.

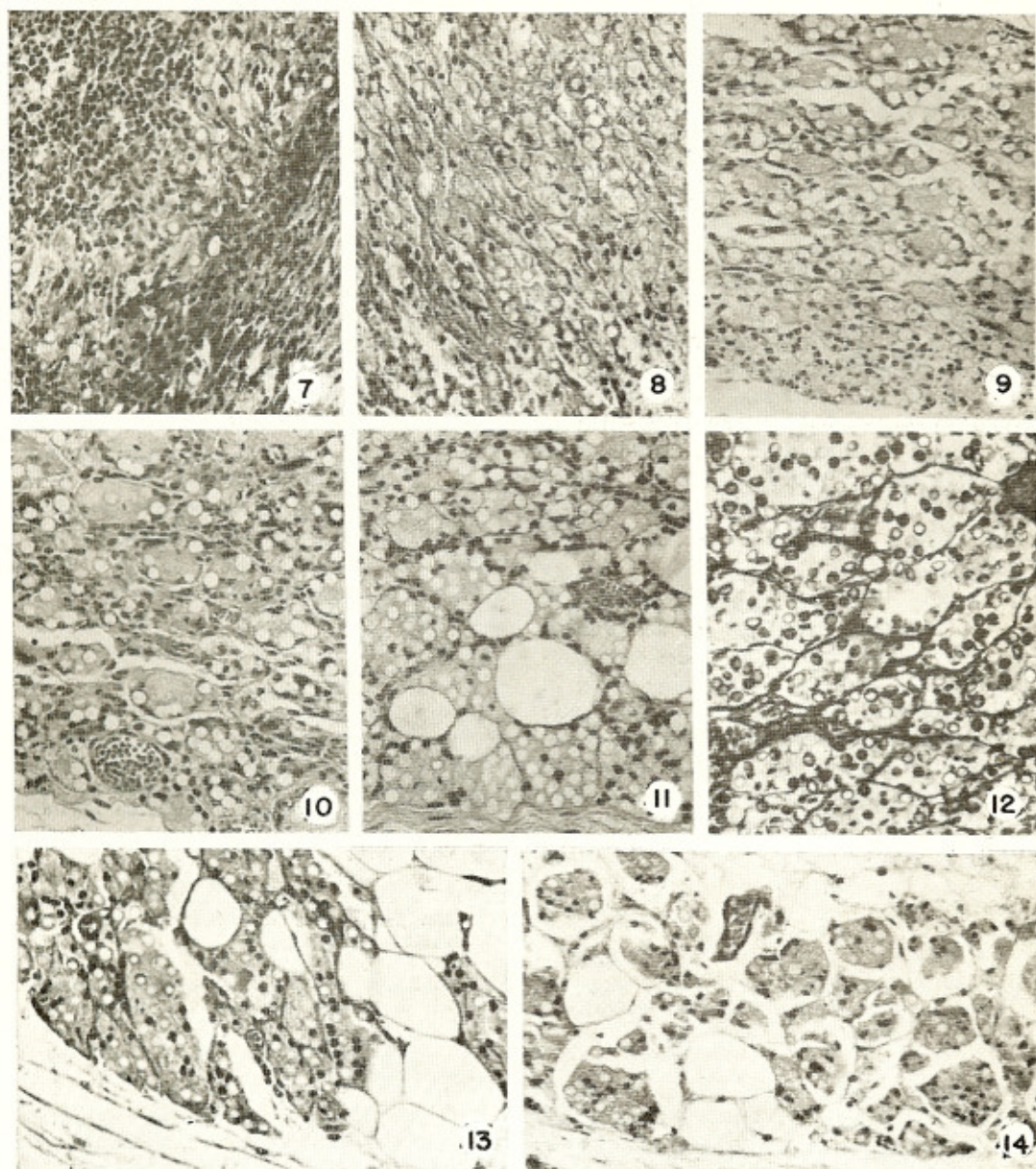


Plate 2 — High power photomicrographs of experimental lesion of Jorge Lóbo's disease produced in the cheek-pouch of the Golden Hamster. (Stained in haematoxylin and eosin). Fig. 7 — 6 day old lesion (Hamster no. 16) 240 X. Fig. 8 — 13 day old lesion (Hamster no. 17) 240 X. Fig. 9 — 20 day old lesion (Hamster no. 15) 240 X. Fig. 10 — 30 day old lesion (Hamster no. 12) 240 X. Fig. 11 — 121 day old lesion (Hamster no. 14) 240 X. Fig. 12 — 121 day old lesion (Hamster no. 14) 240 X but stained in silver stain. Fig. 13 — 101 day old lesion (Hamster no. 8) 189 X. Fig. 14 — 210 day old lesion (Hamster no. 5) 189 X.

DISCUSSION

It is well known that a fungus is responsible for Jorge Lôbo's disease and since the original description of the disease by JORGE LÔBO⁵ various attempts have been made to cultivate it in artificial media or experimentally infest animals, however, all have been unsuccessful. Our experiments have shown the complete reabsorption of the inoculated or implanted host tissue and the gradual formation of a nodule with proliferation of histiocytes and giant cells parasitized with the fungus.

After a few months the lesions in the cheek-pouches are well established and similar to those seen in man. The course of development noted in histological sections showed that the fungus multiplied in the cheek-pouch. The way is now perhaps open for further studies to be made on this disease in the laboratory.

The Authors cannot agree with BILLIGHAM & SILVERS² who said that the cheek-pouch has no lymphatic drainage. In six animals we observed satellite lymph nodes with granulomas and histiocytes containing fungi in their cytoplasm. This suggests that lymphatic drainage of the cheek-pouch does take place. It seems therefore that immune properties attributed to the lack of lymphatic vessels must perhaps be explained in terms of some other mechanism.

RESUMO

Infecção experimental da doença de Jorge Lôbo na bolsa jugal do hamster dourado (Mesocricetus auratus)

O agente etiológico da Doença de Jorge Lôbo inoculado na bolsa jugal de 22 hamsters (*Mesocricetus auratus*) produziu módulos de 1,5 a 5 mm de diâmetro constituídos de histiócitos e células gigantes contendo parasitas. As inoculações subcutâneas de material semelhante nas patas e orelhas de hamsters não produziram quaisquer lesões.

Foi verificada a presença de esporos do fungo até 180 dias depois da primeira ino-

culação. Material infetado da bolsa jugal da primeira inoculação foi reinoculado duas vezes em bolsas jugais de outros hamsters. A histopatologia das lesões produzidas foi a mesma no doador e nos hamsters reinoculados.

De outro lado, tecido mantido durante 41 dias em caldo de cultura de tecido produziu lesões pequenas durante 30 dias, as quais 90 dias depois, não foram mais encontradas.

ACKNOWLEDGMENTS

The Authors are indebted to Doctor Jeffrey Shaw of the University of London for reviewing the manuscript and for his advice. Thanks are also extended to Mrs. Esmeralda Alfaia Costa for her help in the technical work; to Mr. Candido Plácido Sodré of the Museu Paraense Emilio Goeldi for the photomicrographs; and to the Wellcome Parasitology Unit of Instituto Evandro Chagas (FSESP) for supplying the hamsters used in this work.

REFERENCES

1. AZULAY, R. D.; ANDRADE, L. C. & CARNEIRO, J. A. — Micose de Jorge Lôbo. Contribuição ao seu estudo experimental. Inoculações no homem e animais de laboratório e investigação imunológica. *Hospital (Rio)* 73:1165-1172, 1968.
2. BILLIGHAM, R. E. & SILVERS, W. K. — Skin transplants and hamster. *Sci. Amer.* 208:118-127, 1963.
3. BORELLI, D. — Lobomycosis experimental. *Dermat. Venez.* 3:72-82, 1961-1962.
4. DIAS, L. B.; SAMPAIO, M. M. & SILVA, D. — In press.
5. LÔBO, J. — Um caso de blastomicose produzido por uma espécie nova, encontrada em Recife. *Rev. Méd. (Pernambuco)* 1:763-765, 1931.
6. SILVA, D. — Personal information.

Recebido para publicação em 27/8/1969.